

## HEAD AND NECK

# Cervical paragangliomas: single centre experience with 44 cases

## *Paragangliomi cervicali: esperienza monocentrica in 44 casi*

A.M.R. FERRANTE<sup>1</sup>, G. BOSCARINO<sup>1</sup>, M.A. CREA<sup>2</sup>, F. MINELLI<sup>1</sup>, F. SNIDER<sup>1</sup><sup>1</sup> Vascular Surgery Unit and <sup>2</sup> Institute of Anaesthesiology, Università Cattolica del Sacro Cuore School of Medicine - "A. Gemelli" University Hospital Rome, Italy

## SUMMARY

Paragangliomas (PGL) are rare lesions of the neuroendocrine system; in the neck, they usually affect the carotid glomus (carotid body tumours-CBT). This retrospective analysis reports our experience in management of these lesions in patients treated by surgical resection. Between 2000 and 2014, 33 patients were surgically treated at our institution, obtaining a series of 44 cervical PGLs. Tumour characteristics, family history, diagnostic procedures, surgical treatment, short- and long-term outcomes were reviewed. A female prevalence was found (76% of cases). Familial cases occurred in 9 patients (20%); 6 presented with bilateral lesions and 1 had multiple paragangliomas. Lymph node metastasis was not found in any patient. All lesions were classified into three groups according to the latero-lateral diameter. Complete resection of the PGL was performed in all patients. Mortality was null; transitory cranial nerve deficit occurred in 20% of cases with permanent palsy in 6.7%. No perioperative stroke/TIA were observed. Surgical resection of PGL should be considered as the only therapeutic option because it can ensure complete removal of the disease. Patients with bilateral lesions and positive family history should be referred for genetic analysis. Preoperative planning of the surgical procedure by integrated diagnostic imaging and a full mastery of vascular surgery techniques are mandatory to minimise the risk of the most common postoperative complications. Long-term follow-up is recommended, particularly in patients with familial disease or sporadic lesions treated in an advanced stage.

KEY WORDS: Paraganglioma • Carotid body tumour

## RIASSUNTO

*I paragangliomi (PGL) sono tumori rari del sistema neuroendocrino; a livello cervicale, originano nella maggior parte dei casi dal glomo carotideo (Carotid Body Tumor, CBT). Scopo del presente lavoro è illustrare l'esperienza personale maturata dagli Autori sul trattamento chirurgico di queste lesioni. Tra il 2000 e il 2014, 33 pazienti sono stati sottoposti a exeresi di complessivi 44 PGL presso la nostra Unità Operativa. Sono state analizzate retrospettivamente le caratteristiche epidemiologiche, strumentali, operatorie nonché i risultati immediati e lungo termine. È risultata evidente una prevalenza di pazienti di sesso femminile (76%); forme familiari sono state osservate in 9 casi (20%), nei quali abbiamo osservato 3 lesioni bilaterali e, in un paziente, lesioni multifocali. Non sono mai state rilevate metastasi ai linfonodi regionali. I PGL sono stati classificati secondo criteri dimensionali utilizzando il massimo diametro latero-laterale. La rimozione della lesione è stata completa in tutti i pazienti. La mortalità operatoria è stata nulla; deficit transitori a livello dei nervi cranici sono stati osservati nel 20% dei casi ma una paralisi permanente è risultata evidente solo nel 6,7%. Non abbiamo osservato perioperatoriamente alcun caso di ictus/TIA. L'exeresi chirurgica del PGL è da considerare, a nostra opinione, l'unica reale opzione terapeutica in quanto permette la completa rimozione della neoplasia. L'analisi genetica è consigliabile nelle lesioni bilaterali e nei casi di familiarità. Una strategia operatoria pianificata mediante l'integrazione delle tecniche di imaging, e una piena padronanza della tecnica chirurgica vascolare sono indispensabili per ridurre al minimo i rischi delle complicanze peroperatorie più comuni. Nei pazienti operati è indispensabile un follow-up a lungo termine, soprattutto nei casi di familiarità o di lesioni sporadiche trattate in stadio avanzato.*

PAROLE CHIAVE: Paraganglioma • Tumore del glomo carotideo

Acta Otorhinolaryngol Ital 2015;35:88-92

## Introduction

Paragangliomas (PGLs) are rare lesions, with an incidence of 1:30.000 but are the most common tumours of extra-adrenal chromaffin tissue and represent more than 50% of head and neck paragangliomas<sup>1</sup>. These tumours are benign in the majority of the cases, but clinical malignant behaviour is described in 5-30% of cases. Most CBTs

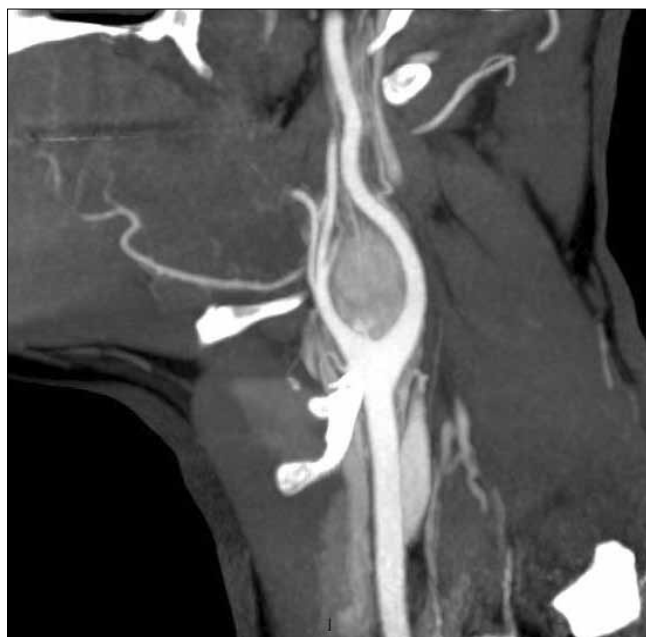occur in adults between 30 and 60 years<sup>2</sup>, although cases with earlier outset due to genetic inheritance have been reported<sup>3</sup>. CBTs have been associated with nine susceptibility genes: NF1, RET, VHL, SDHA, SDHB, SDHC, SDHD, SDHAF2 (SDH5) and TMEM127; hereditary tumours are mostly caused by mutations of the SDHD gene, but SDHB and SDHC mutations are not uncommon in such patients; moreover, they are rarely associated with

mutations of VHL, RET, or NF1. Further investigations on SDHA, SDHAF2 and TMEM127 are on-going<sup>4</sup>. Sex prevalence is controversial.

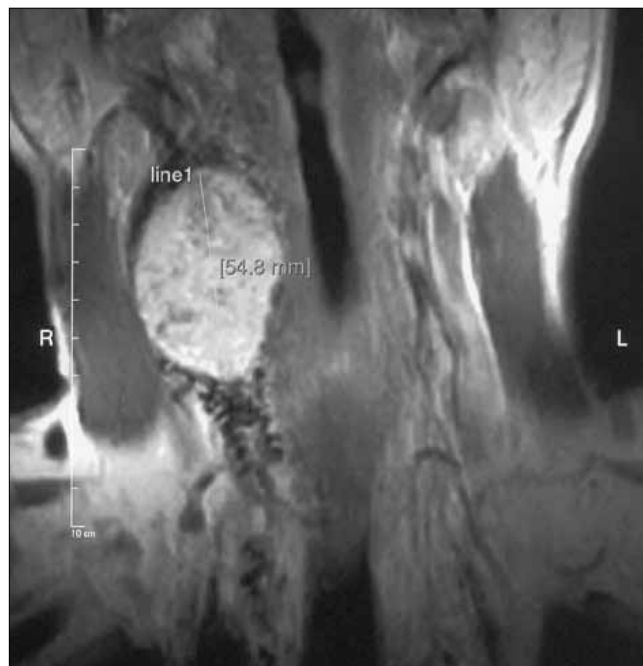
CBTs are space-occupying tumours, and therefore signs and symptoms are induced by compression on the surrounding anatomical structures. Due to its slow growth, the most common clinical presentation of CBT is a painless mass in the latero-cervical region. Surgical excision is the only treatment that can provide complete eradication of the disease, considering that histological evaluation is unable to provide a definitive diagnosis of malignancy<sup>5,6</sup>.

## Materials and methods

Between 1988 and the time of writing, 33 patients with 44 CBTs have been treated by surgical excision in our unit: 7 men and 26 women with mean age of 55 years. In 16 (48%) patients, the lesion was asymptomatic and diagnosis was incidentally made by ultrasound scan performed for another reason; 15 (45%) patients presented a painless mass in the latero-cervical region; only 2 (7%) patients reported symptoms such as headache, palpitations and local pain. First evaluation was performed, in all patients, by duplex ultrasound. All patients admitted were previously diagnosed by second level examination such as angioCT scan (Fig. 1) or angio MRI scan (Fig. 2) and <sup>131</sup>I-MIBG scintigraphy. A detailed list of imaging procedures performed in all patients is given in Table I. Familial cases occurred in 9 patients (20%); of these, 3 patients had bilateral lesions and 1 patient had multiple paragangliomas. No lymph node metastasis was found at preoperative imaging in any case. The lesions were classified into three groups according to



**Fig. 1.** Coronal view with angio-MRI showing the typical "salt-pepper" pattern of a CBT.

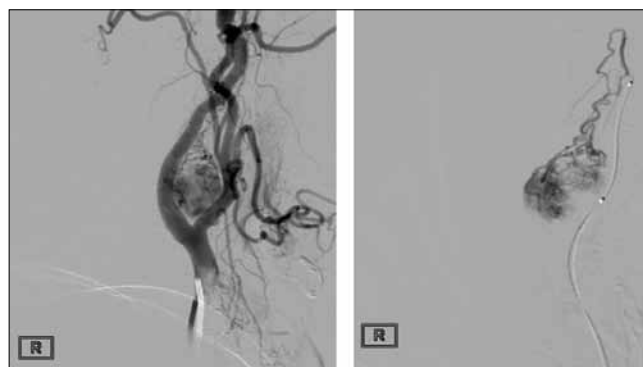


**Fig. 2.** MIP reconstruction from high-resolution angio-CT scan of a CBT: in addition to the peculiar contrast uptake by CBT and the "cup" appearance of the carotid bifurcation, the detailed view of vascular anatomy is comparable to a conventional angiographic study.

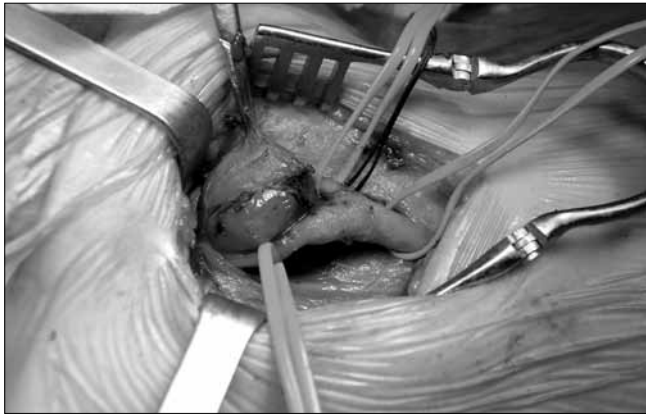
the latero-lateral diameter: 17 tumours (40%) in Group I (< 3 cm), 19 (44%) in Group II (3-5 cm), and 8 (16%) in Group III (> 5 cm). Tumours that extended to the skull base were not included in this series. In 22 cases (group II-III), preoperative embolisation of the CBT feeding vessels was performed by superselective carotid angiography (Fig. 3).

**Table I.** Preoperative imaging techniques in 33 patients.

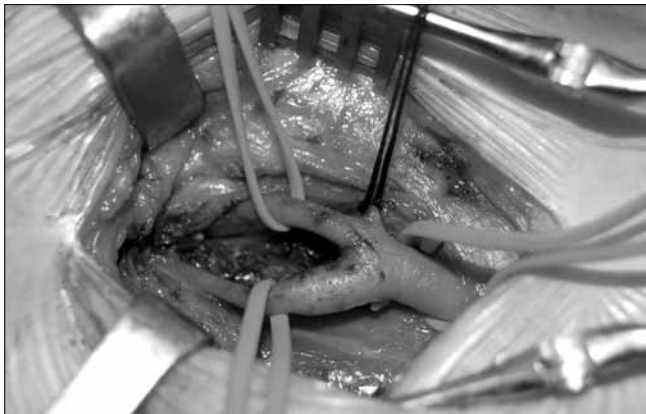Duplex ultrasound	44 (100%)
Angio-CT	23 (52%)
Angio-MRI	14 (32%)
Angiography	22 (50%)
PET-CT	1 (2.3%)
MIBG	1 (2.3%)



**Fig. 3.** Diagnostic selective carotid angiography (on the left) and superselective embolisation (on the right) of feeding vessels of a CBT.



**Fig. 4.** Intraoperative view of a CBT: the carotid bifurcation is exposed and its branches secured on silicone loops before starting tumour resection.



**Fig. 5.** Intraoperative view of the cleared carotid bifurcation.

Preoperative and postoperative laryngoscopy as well as phoniatric evaluation were performed in all patients. All lesions were treated by the same surgeon (F.S.) by complete surgical resection through a conventional approach to the carotid artery and its bifurcation (Figs. 4, 5); all interventions were performed under general anaesthesia.

The follow-up protocol included yearly clinical evaluation and duplex ultrasound of the neck.

## Results

Operative mortality was null; no strokes were observed prior surgery or in the immediate postoperative period. Surgical revision was needed for postoperative bleeding in 1 case. The incidence of transient peripheral neurologic complications was 16% (7 cases). In 6 cases partial or complete encasement of the vagus nerve was found at surgical exploration; although this increased the difficulty of the procedure, the nerve was preserved by a meticulous dissection from the tumour. We observed only 2 (4.5%) permanent lesions, both affecting the X cranial nerve: in one case in group II, dysphonia from recurrent laryngeal nerve palsy was observed after *en bloc* resection of

**Table II.** Postoperative complications following 44 CBT resections.

	Group 1	Group 2	Group 3
Permanent cranial nerve palsy	0	1	1
Horner's syndrome	0	1	0
Hypertension	1	1	0
Stroke	0	0	0
Dysphagia / transient sore throat	3	1	2
Bleeding	0	1	0

a paraganglioma arising from the vagus (the same patient – already underwent bilateral removal of CBT – presented postoperative arterial hypertension treated with clonidine and  $\beta$ -blockers); in the other case, a type III CBT tightly adherent to the vagus was successfully resected sparing the nerve, but postoperatively complained of permanent dysgeusia. Detailed complications are listed in Table II. In 1 of 44 (2.3%) interventions, a tight adhesion of the tumour to the posterior wall of the carotid bulb was found, requiring a resection-anastomosis of the first portion of the internal carotid artery. One of the two cases of suspected recurrent CBT was found intraoperatively to be a metachronous primary paraganglioma of the vagus nerve, which was treated by *en bloc* resection of the nerve containing the tumour. The other case was a local recurrence found during follow-up, in a case with family history of disease, 2 months after resection of the primary lesion. All resected lymph nodes were negative for metastasis at histologic examination.

## Discussion

CBT are rare lesions and their optimal treatment deserves some considerations that we have gained from our experience in the last 14 years. The incidence of familial CBTs in our series (20%) is similar to other series<sup>6-8</sup>, and the finding of painless mass as the most common clinical presentation is also in agreement with other authors<sup>9,10</sup>. A female prevalence has been reported in some series, but has not been observed in other reports<sup>11</sup>. Preoperative diagnostic imaging is crucial; differential diagnosis is with thyroid nodule, lymphadenopathy and brachial cysts. Fine-needle aspiration biopsy (FNAB) as preoperative diagnostic tool is absolutely not indicated because of the hypervascularisation of the tumour, and its proximity to nervous and vascular structures makes the procedure extremely dangerous; moreover, the risk of dissemination is not negligible and – last but not least – cytologic evaluation cannot differentiate benign from malignant lesions. In our series, 3 of 33 patients had previous FNAB in other hospitals.

The use of different types of non-invasive imaging techniques can provide correct diagnosis in most cases with satisfactory sensitivity and specificity. Duplex ultrasound scan is usually the first diagnostic exam; it can provide information on tumour size and location, relationships with the vascular structures and intralesional flow patterns. Angio-CT

scan and angio-NMR provide further details about regional extension of the tumour and eventual vascular encasement; hypervascularised PGL shows characteristic features that are helpful for differential diagnosis. Selective carotid angiography can identify the feeding vessels of the tumour, usually rising from the pharyngeal and external carotid artery: however, this information can be provided by latest generation multilayer CT scanners, and the use of an invasive procedure is advisable only to perform a superselective embolisation aimed at obtaining preoperative PGL shrinkage, reduced vascularisation of the mass and contained risk of intraoperative bleeding<sup>12-14</sup>. Preoperative embolisation is therefore particularly useful in large and hypervascularised tumours (group II-III)<sup>8 12</sup>; in our practice, we prefer to perform embolisation the day before the surgical procedure to avoid any perilesional inflammatory reaction and to achieve the best reduction of intraoperative bleeding; re-adsorbable material (shredded gelatine sponge) was used in our early experience, while we currently prefer non-reabsorbable agents such as PVA (polyvinyl alcohol) particles.

In our series, 22 patients (all with tumour size > 3 cm) underwent the procedure because of suspected vagus nerve encasement at CT (1 case) or hypervascularisation signal at duplex ultrasound scan. However, in a large series<sup>15</sup>, the procedure does not seem to affect the rate of cranial nerve injuries – although most are temporary; some authors do not use embolisation at all<sup>11</sup> and others<sup>16</sup> recommend it in a few selected cases (size > 5 cm, Shamblin's type III, or significant cranial extension). Recently, the insertion of a covered stent in the external carotid artery has been sporadically reported as an alternative method to embolisation<sup>17</sup>; assuming a young age of most patients and the risk of early and late complications, we consider the choice of permanently stenting a normal vessel highly questionable. Unlike extraadrenal chromaffin tissue tumours, CBTs rarely secrete vasoactive substances; we have no clinical nor laboratory findings suggestive of endocrine activity in any of our patients. However, according to the literature<sup>18 19</sup>, the use of a nuclear medicine imaging technique such as MIBG, PET-CT, or Octreoscan is highly recommended as complementary study for total body investigation in familial cases or multifocal disease.

In our series, we did not adopt the classification criteria proposed by Shamblin<sup>20</sup>, because we consider this classification useful for predicting vascular morbidity but not neurological morbidity<sup>21</sup>. The risk of intraoperative cranial nerve injury proportionally increases with the size and extension of tumour, with higher rates observed in bilateral and/or large lesions<sup>8 22-24</sup>; for this reason, also considering potential forensic implications, it is mandatory to assess the preoperative status of cranial nerves (VII, X, XI, XII) that are potentially at risk of intraoperative injury.

General anaesthesia is routine for safe PGL surgery; in our experience, sevoflurane is the hypnotic of choice since it assures haemodynamic steadiness through a lower vaso-

dilatory action compared to other halogenated agents; moreover, it preserves the microcirculatory self-regulation. Remifentanyl provides optimal analgesia during the surgical procedure; due to its very fast kinetics, awakening is almost immediate when its administration is stopped<sup>25</sup>.

The surgical procedure must include regional lymph nodes with enlarged size, suspicious morphology, or closely adherent to the tumour. Accurate dissection of the principal regional nerves from the PGL is needed. Careful excision of the tumour using microsurgical instruments and bipolar cautery can be performed along a sub adventitial plane or "white line" as suggested by Gordon Taylor<sup>24</sup>; only in this way it is possible to separate the lesion from the surrounding vessels by slipping on a relatively avascular plane<sup>26 27</sup>. In the present series vascular reconstruction was necessary in only one case; this is a particularly good result compared with the higher rates reported in the literature<sup>12</sup>. In our opinion, solid experience in carotid surgery is crucial to minimise arterial and nerve lesions, as well to perform eventual vessel reconstructions.

When faced with large PGLs that extend cranially to the skull base, a multidisciplinary team is recommended, including an otolaryngologist or maxillofacial surgeons, to obtain the best exposure through a surgical approach including standard or modified mandibulotomy<sup>28 29</sup>.

## Conclusions

The development of imaging techniques improved the opportunity to correctly diagnose CBTs, but an integrated multidisciplinary approach is essential for planning the best treatment and providing the best outcome<sup>28</sup>. On the basis of our personal experience and of the reported experiences, we can draw some conclusions:

- Surgical resection of cervical paragangliomas is the only curative treatment and should be considered as the first therapeutic option<sup>5 6</sup>.
- PGL removal is a challenging surgery because of the tumour's location near large vascular structures and cranial nerves. Therefore, an experienced vascular surgical team is recommended, also for correct management of eventual vascular complications. Excision should be as conservative as possible in preserving main vessels and adjacent nerves; extensive resections should be limited to cases of actual locoregional invasion to minimise the risk of complications, with particular reference to neurologic ones (transitory and/or permanent).
- Tumours associated with succinate dehydrogenase (SDH) mutations show more aggressive behaviour. For this reason, some authors recommend family screening as routine in patients with hereditary paraganglioma carotid for early diagnosis and treatment<sup>30-32</sup>.
- Histological criteria of malignancy do not apply to CBTs; for this reason, lifelong follow-up is crucial, particularly in patients with familial disease or sporadic lesions in an advanced stage.



## References

- 1 Pellitteri PK, Rinaldo A, Myssiorek D, et al. *Paragangliomas of the head and neck*. Oral Oncology 2004;40:563-7.
- 2 Lack E, Cubilla A, Woodrug J, et al. *Paragangliomas of the neck region*. Cancer 1977;39:397-409.
- 3 Georgiadis GS, Lazarides MK, Tsalkidis A. *Carotid body tumor in a 13-years-old child: Case report and review of the literature*. J Vasc Surg 2008;47:874-80e2.
- 4 Offergeld C, Brase C, Yaremchuk S, et al. *Head and neck paragangliomas: clinical and molecular genetic classification*. Clinics 2012;67(Suppl 1):19-28.
- 5 Dimakakos PB, Kotsis TE. *Carotid body paraganglioma: review and surgical management*. Eur J Plast Surg 2001;24:58-65.
- 6 Ma D, Liu M, Yang H. *Diagnosis and surgical treatment of carotid body tumor: a report of 18 cases*. J Cardiovasc Dis Res 2010;1:122-4.
- 7 Sajid MS, Hamilton G, Baker DM. *A multicenter review of carotid body tumour management*. Eur J Vasc Endovasc Surg 2007; 34:127-30.
- 8 Qin RF, Shi LF, Liu YP. *Diagnosis and surgical treatment of carotid body tumors: 25 years' experience in China*. Int J Oral Maxillofac Surg 2009;38:713-8.
- 9 Farr HW. *Carotid body tumors: a 40 year study*. CA Cancer J Clin 1980;36:260-5.
- 10 Lee JH, Barich F, Karnell LH. *National cancer database report on malignant paragangliomas of head and neck*. Cancer 2002;94:730-7.
- 11 Gad A, Sayed A, Elwan H, et al. *Carotid body tumors: a review of 25 years experience in diagnosis and management of 56 tumors*. Ann Vasc Dis 2014;7:292-9.
- 12 Dardik A, Eisele DW, Williams GM. *A contemporary assessment of carotid body tumor surgery*. Vasc Endovasc Surg 2002;36:277-83.
- 13 Gwon JG, Kwon T-W, Kim H. *Risk factors for stroke during surgery for carotid body tumors*. World J Surg 2011;35:2154-8.
- 14 Litle VR, Reilly LM, Ramos TK. *Preoperative embolization of carotid body tumors: when is it appropriate?* Ann Vasc Surg 1996;10:464-8.
- 15 Power AH, Bower TC, Kasperbauer J, et al. *Impact of pre-operative embolization on outcomes of carotid body tumor resections*. J Vasc Surg 2012;56:979-89.
- 16 Kakkos SK, Reddy DJ, Shepard AD, et al. *Contemporary presentation and evolution of management of neck paragangliomas*. J Vasc Surg 2009;49:1365-73.e2.
- 17 Scanlon JM, Lustgarten JJ, Karr SB, et al. *Successful devascularization of carotid body tumors by covered stent placement in the external carotid artery*. J Vasc Surg 2008;48:1322-4.
- 18 Taïeb B, Neumann H, Rubello D, et al. *Modern nuclear imaging for paragangliomas: beyond SPECT*. J Nucl Med 2012;53:264-74.
- 19 Wisotzki C, Jacobsen F, Salamon J, et al. *Synchronous ileocecal neuroendocrine tumor and carotid chemodectoma - diagnosis by <sup>111</sup>In pentetretotide SPECT/CT*. Clin Nucl Med 2014;39:547-8.
- 20 Shamblin WR, Remine WH, Sheps SG. *Carotid body tumor (chemodectoma). Clinicopathologic analysis of 90 cases*. Am J Surg 1971;122:732-9.
- 21 Luna-Ortiz K, Rascon-Ortiz M, Villavicencio-Valencia V, et al. *Does Shamblin's classification predict postoperative morbidity in carotid body tumors? (A proposal to modify Shamblin's classification)*. Eur Arch Otorhinolaryngol 2006;263:171-5.
- 22 Makeieff M, Raingeard I, Bonafe A. *Surgical management of carotid body tumors*. Ann Surg Oncol 2008;15:2180-6.
- 23 Dongyang M, Lanzhong L, Hong Y. *A retrospective study in management of carotid body tumor*. J Oral and Maxillofac Surg 2009;47:461-5.
- 24 Gordon-Taylor G. *On carotid body tumors*. BMJ 1982;284:1507-8.
- 25 De Blasi RA, Palmisani S, Boezi M, et al. *Effects of remifentanyl-based general anaesthesia with propofol or sevoflurane on muscle microcirculation as assessed by near-infrared spectroscopy*. Br J Anaesth 2008;101:171-7.
- 26 Luna-Ortiz K, Villavicencio-Valencia V, Carmona-Luna T. *Carotid body tumor resection with Ligasure® device*. Acta Otorinolaringol Esp 2009;61:6-11.
- 27 Jia MY, Wang HF. *Resection of carotid body tumor under interrupted block of common carotid artery*. Shanghai J Stomatol 2005;14:200-2.
- 28 Kasper GC, Welling RE, Wladis AR, et al. *A multidisciplinary approach to carotid paragangliomas*. Vasc Endovascular Surg 2006;40:467-74.
- 29 Vikatmaa P, Mäkitie AA, Railo M, et al. *Midline mandibulotomy and interposition grafting for lesions involving the internal carotid artery below the skull base*. J Vasc Surg 2009;49:86-92.
- 30 Carriero A, Rossner G, Nuzzo A. *Paragangliomi del collo a carattere familiare: imaging integrato e pianificazione dello screening familiare*. Radiol Med 1990;79:297-301.
- 31 Ellis RJ, Patel D, Prodanov T, et al. *The presence of SDHB mutations should modify surgical indications for carotid body paragangliomas*. Ann Surg 2014;260:158-62.
- 32 Fruhmans J, Geigl JB, Konstantiniuk P, et al. *Paraganglioma of the Carotid Body: Treatment Strategy and SDH-gene Mutations*. Eur J Vasc Endovasc Surg 2013;45:431-6.

Received: February 11, 2015 - Accepted: March 8, 2015

Address for correspondence: Angela M.R. Ferrante, Università Cattolica del Sacro Cuore, Vascular Surgery Unit, "A. Gemelli" Hospital, I.go A. Gemelli 1, 00168 Rome, Italy. Tel. +39 06 30156126. Fax +39 06 30155951. E-mail: aferrante@rm.unicatt.it